Aviesan
alliance nationale pour les sciences de la vie et de la santé

Institut Thématique Multi-Organismes
Technologies pour la santé

Effets de la compaction d'un greffon osseux sur son ostéogénèse en vue de chirurgie réparatrice de fentes palatines

C. DISSAUX [1], H. PETITE [2], M. BENSIDHOUM [2], D. GEORGE [3] and Y. REMOND [3]

[1] Service de chirurgie maxillo-faciale et plastique, Hôpitaux universitaires de Strasbourg, 67000 Strasbourg, FRANCE
[2] B2OA, UMR CNRS, Paris Descartes, Paris, FRANCE
3 ICUBE, CNRS, Université de Strasbourg, 67000 Strasbourg, FRANCE

Contact : Caroline Dissaux – carodissaux@gmail.com

Context

Cleft lip and palate, standing as the most frequent craniofacial malformation (1/700 newborns) require several surgeries in the first year of life to close the lip, repair the nose and reform hard and soft palate.
Alveolar cleft is left opened not to impair maxillary growth (Robertson, 1968). A bone graft is yet necessary to restore maxillary union, allow teeth eruption and provide a support for lip and nose (Witsenburg, 1985).
Secondary alveolar bone graft (Boyne and Sands, 1972) present good but variable results (Borba et al., 2013; Dissaux et al., 2016).

Raised questions :

- What is the best age to perform the alveolar bone graft ?
- Which is the best bone to use ? What should be the right density, porosity ?
- What is the right compression to use while the surgeon places the graft ?
- Is the graft only osteoconductive ? Do the grafted cells really integrate and form new bone ?
- Do cells from the nasal floor play a role in osteoformation?

Despite its usual use in everyday surgical practice, bone graft integration biology and mechanism are not well understood.

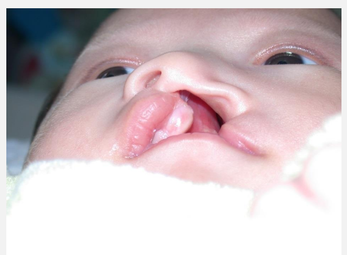

Unilateral Cleft Lip and Palate: involves lip, dental arch, soft and hard palate

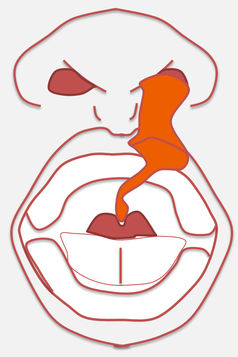

Bone graft of the alveolar defect

Left alveolar graft

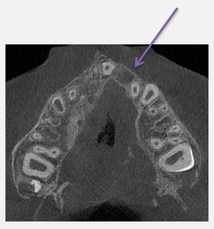

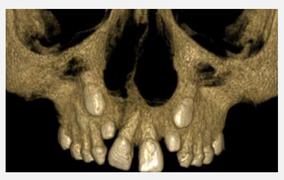

Cone Beam Imagery (CBCT) and its reconstruction in 3D alveolar bone graft

Objectives

- Alveolar bone graft can appear as a very complex process (Helm et al., 2007) but only a good comprehension of the mechanisms and the influencing factors could allow the surgeon to obtain better and more predictible results.
- First we study of the structure, the biological composition and the growth factors release of cancellous bone cylinders taken from human femoral heads.

Particularity of the alveolar bone graft

The neo-osteogenesis occurring in the case of alveolar bone graft is different from fracture healing (Meyer et al., 2006) as two cortical bone surfaces are involved and bone synthesis in this small alveolar cleft space and cannot occur only by abrading. During alveolar bone grafting the surgeon places iliac cancellous bone in a 3-D space, between 2 cortical bones, with smooth upper and bottom layers (nasal floor, gingival mucosa) and applies a compression force on the graft. cortical bone.

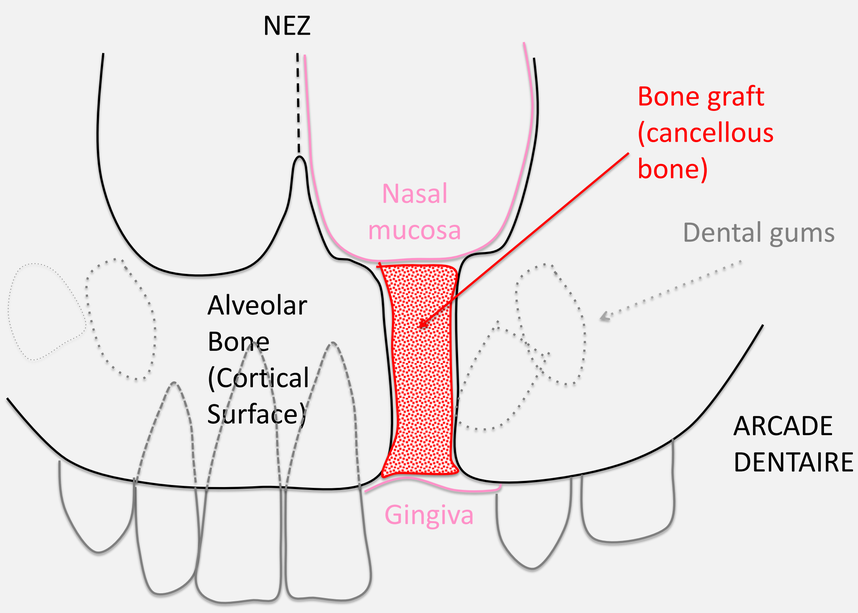

Experiments

- A compression force is applied to a fixed geometry of cancellous bone. The force goes from 0 to 50 N .
- Analysis and Numbering of CFU-F (Cells colonies of stem cells).

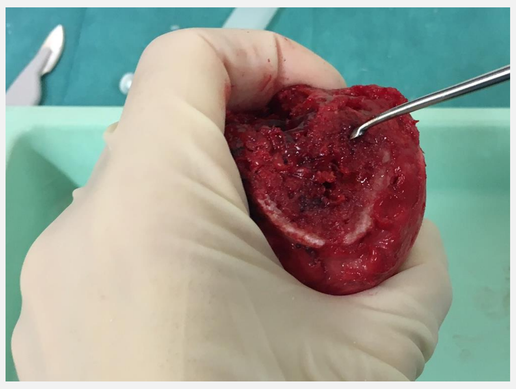

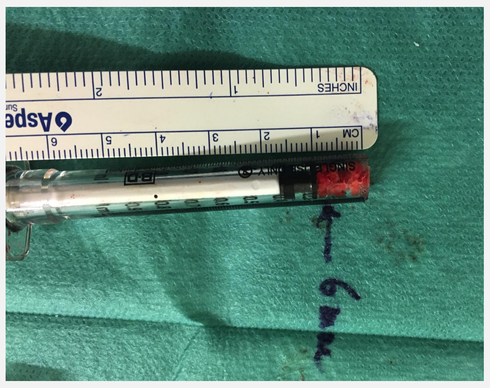

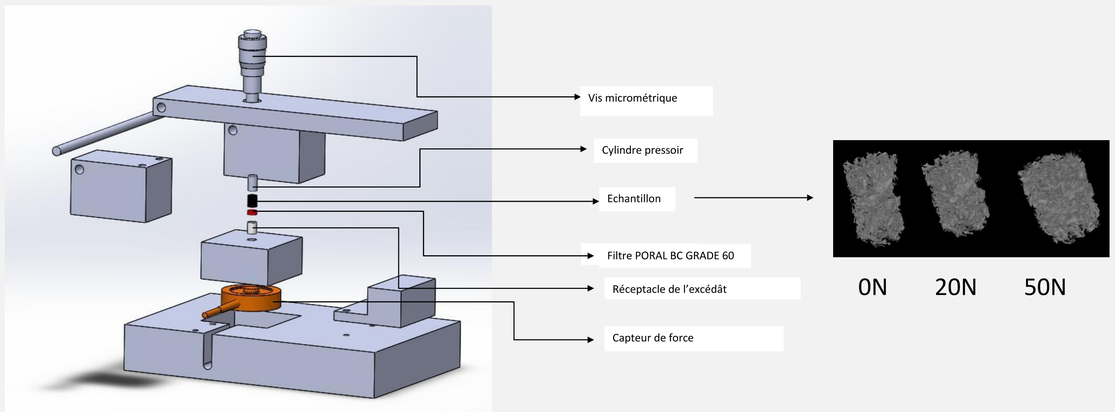

Conclusion

This study is a first step to understand the biomechanical activity of cancellous bone when a surgeon applies a compression force at the time of the graft placement, before an in vivo phase where the interface between bone graft and recipient site will be analyzed.

Perspectives

- Second phase with small animal study
- Enter these experimental data to a numerical simulation model of bone reconstruction in alveolar cleft.

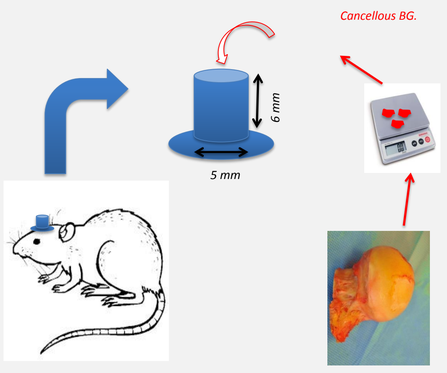

References

- *Boyne, et al., J. Oral Surg. 3(2) : 87-92, 1972*
- Witsenburg, *J Maxillofac Surg.* 13:197-208, 1985
- Helms, et al., *Bone*, 41: 479-85, 2007.
- Borba, et al., *Br J Oral Maxillofac Surg*. 52:174-178, 2013
- Dissaux, et al., *J Craniomaxillofac Surg*. 44 : 21-6, 2016.
- George, et al., Bio-Medical Mat. Eng., 28(S1), S15-S27, 2017.